Understanding Coccidiosis Control with Anticoccidials

Coccidiosis and optimizing potential do not work together.

Coccidiosis in poultry refers to a disease in which a bird's intestinal walls are damaged by protozoan parasites called coccidia. This damage compromises the bird's ability to absorb nutrients and can subsequently lead to decreased weight gain, impaired feed efficiency and eventually, mortality. Because coccidia are present in most modern poultry-producing facilities, coccidiosis poses a significant threat to the success of broiler producers.

Fortunately, there are safe anticoccidial compounds that can effectively reduce infection pressure to a level that has little or no impact on flock development.

Coccidiosis can negatively impact feed efficiency.

Coccidia are found in virtually every poultry-rearing operation worldwide. The coccidia parasites are very prolific and the oocysts (the zygote, or earliest life stage of the coccidia) are highly resistant to destruction. In fact, depending on the species of coccidia, a single oocyst ingested by one bird can result in approximately 400,000 new oocysts being excreted.

During their complex life cycle, the different developmental stages of the coccidia will destroy vast numbers of intestinal cells in infected birds. The level of damage is directly related to three factors:

1) The number of coccidia that are ingested and able to complete their life cycle
2) The species of coccidia, which determines the part of the intestinal tract that is affected and pathogenicity of the infecting species (Table 1)
3) The reproductive rate capacity (Table 2)

Table 1: Sites of Infection and Pathogenicity

Species	Site of Infection	Pathogenicity
E. acervulina	upper intestine	moderate
E. maxima	middle intestine	moderate
E. necatrix	middle intestine	high
E. brunetti	lower intestine	moderate
E. tenella	ceca	high

Barnfield and Forbes 1999

Table 2: Theoretical Reproductive Potential

Species	Number of Schizonta	Maximum Measured Reproduction Resulting From 1 Ingested Oocyst
E. acervulina	4	72,000
E. maxima	2	12,000
E. necatrix	1+1	58,000
E. brunetti	2	400,000
E. tenella	2(3)	400,000

racket and Bliznick 1951

Table 3: Prepatent Period and Sporulation Time

Species	Minimum Prepatent Time (hours)	Minimum Sporulation Time (hours)
E. acervulina	97	17
E. maxima	121	30
E. necatrix	138	18
E. brunetti	120	18
E. tenella	115	18

Long and Reid, University of Georgia

Coccidia infect poultry through oral intake of sporulated oocysts. These microscopic egg-like bodies are passed in the droppings of birds infected with cecal or intestinal coccidiosis.



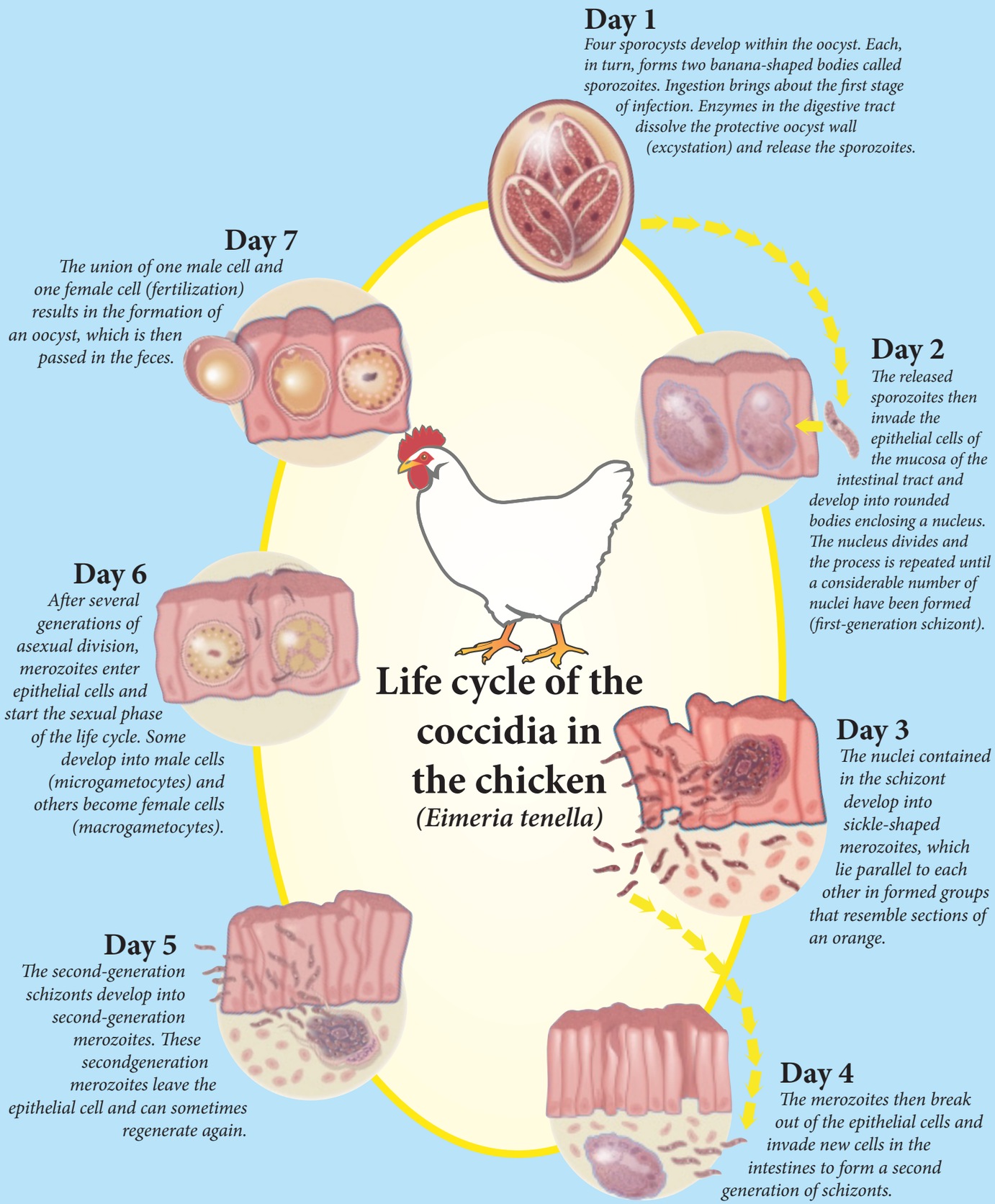

Three conditions are needed for oocysts to sporulate and become infective: high moisture, oxygen (aerobic environment) and adequate temperature. Only in the presence of all three conditions can the parasite develop to the infective stage.

When a bird that is fed an anticoccidial-free diet becomes infected, damage to the bird's intestinal tract is inevitable. This damage impairs the bird's ability to utilize nutrients in the feed. This impairment can lead to growth depression, poor feed conversion, increased mortality and increased risk of secondary infections.

Studies have shown that even subclinical levels of infection can affect weight gain, feed conversion and skin pigmentation.

The damage caused by various species of coccidia.

	E. acervulina	*E. brunetti*	*E. maxima*	*E. mivati*	*E. tenella*	*E. necatrix*
+1	 Scattered, white, plaque-like lesions containing developing oocysts confined to the duodenum. These lesions are elongated with the longer axis transversely oriented on the intestinal walls like the rungs of a ladder. They may be seen from either the serosal or mucosal intestinal surfaces. They may range up to a maximum of five lesions per square centimeter.	 There are no gross lesions. In the presence of distinct lesions, parasites may go undetected unless scrapings from suspicious areas are examined microscopically.	 Small red petechiae may appear on the serosal side of the midintestine. There is no ballooning or thickening of the intestine, though small amounts of orange mucus may be present.	 Scattered, small, white, plaque-like lesions in the duodenum, similar to those observed for *E. acervulina*, except that the individual lesion is more rounded and observable from either the serosal or mucosal surface.	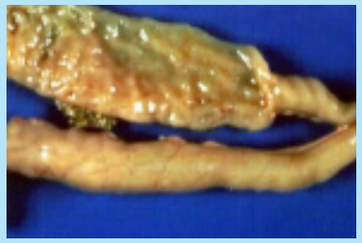 There are very few scattered petechiae on the cecal wall and there is no thickening of the cecal wall. Normal cecal contents are present.	 Small scattered petechiae and white spots are easily seen from the serosal side. Little, if any, damage is apparent on the mucosal surface.
+2	 Lesions are much closer together, but not coalescent. They may extend as far posterior as 20 cm below the duodenum in 3-week-old birds. The intestinal walls show no thickening. Digestive tract contents are normal.	 The intestinal wall may appear grey in color. The lower portion may be thickened. Flecks of salmon-colored material sloughed off from the intestine are present. Petechial hemorrhages can also be present.	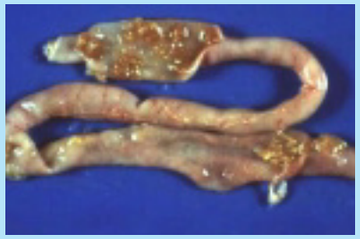 The serosal surface may be speckled with numerous red petechiae, and the intestine may be filled with orange mucus. There is little or no ballooning of the intestine. The intestinal wall will be thickened.	 Lesions are much closer together and will extend in the posterior direction beyond the duodenum. The intestinal wall may or may not thicken. Digestive contents usually are normal.	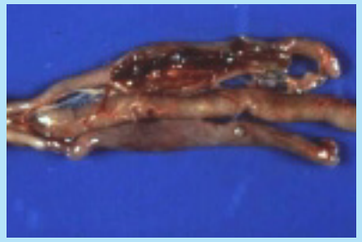 Lesions are more numerous, with noticeable blood in the cecal contents. The cecal wall is somewhat thickened. Normal cecal contents are present.	 Numerous petechiae are visible on the serosal surface. A slight ballooning confined to the midgut area may be present.
+3	 Lesions are numerous enough to cause coalescence in the lesion size, giving the intestine a coated appearance. The intestinal wall is thickened and the contents are watery. Lesions may extend as far posterior as the yolk sac diverticulum.	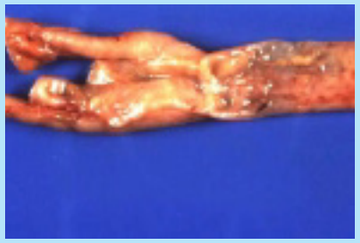 The intestinal wall is thickened and a bloodtinged catarrhal exudate is present. Transverse red streaks may be present in the lower rectum and lesions occur in the cecal tonsils. Soft mucus plugs may be present in this area.	 The intestinal wall is ballooned and thickened. The mucosal surface is roughened and the intestinal contents are filled with pinpoint blood clots and mucus.	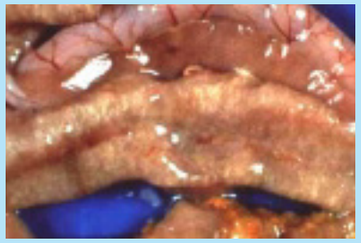 Lesions are numerous and the intestinal wall thickens, similar to *E. acervulina* except that severe congestion has not been noted for *E. mivati*. The intestinal wall is thickened and the contents are watery. With the progression of the infection, E. mivati has a tendency to move in the posterior direction into midjejunum and ileum.	 Large amounts of blood or cecal cores are present. Cecal walls are greatly thickened. Little, if any, fecal contents are present in the ceca.	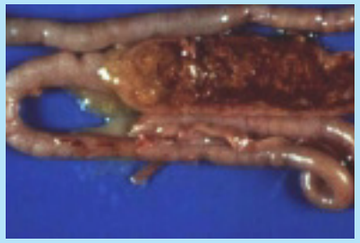 There is extensive hemorrhaging into the lumen of the intestine and the serosal surface is covered with red petechiae and/or white plaques. The serosal surface is rough and thickened with many pinpoint hemorrhages. Normal intestinal contents are lacking. Ballooning extends over the lower half of the small intestine.
+4	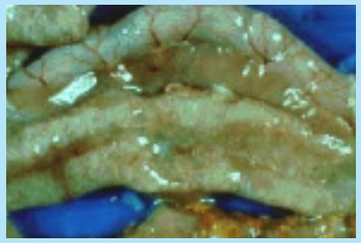 Coalescing of the lesions is so complete and no distinctive lesions may appear in the duodenal portion of the intestine. Milder infections with distinctive white plaques are recognized. The intestinal wall is considerably thickened and the roughened intestinal wall will be laden with oocysts. Diarrhea, severe weigh loss, poor feed conversion and skin depigmentation accompany such an infection in nonmedicated birds.	 Severe hemorrhage and coagulated blood in lower small intestine.	 Excessive hemorrhaging, mucus, watery fecal material, undigested food particles and areas of necrosis.	 Lesions are much closer together and will extend in the posterior direction beyond the duodenum. The intestinal wall may or may not thicken. Digestive contents usually are normal.	 Blood-filled cecal pouches.	 Mid small intestine ballooned. Intestinal wall thickened with “salt and pepper” appearance. Heavy mucus production, massive hemorrhaging and coagulated blood.

Solving the coccidiosis problem.

Coccidia are found wherever chickens are raised. Controlling coccidiosis in your flock is essential to maintaining the success of your broiler operation. That coccidia parasites will be present is a virtual certainty. Left untreated, coccidiosis infection pressure will lead to poor feed efficiency, reduced weight gain, secondary illness and potentially widespread mortality. However, based on research, broilers fed anticoccidial compounds show evidence of increased body weight and improved feed conversion and a better health status. The challenge of controlling coccidiosis is twofold:

Goal 1 - Keep infection pressure low

The tremendous reproductive capability of coccidia can result in enormous infection pressure in a relatively short period. And due to the resilient and ubiquitous nature of coccidia, eradication is not a practical option. Therefore, the first goal of all coccidiosis control programs is to prevent potentially devastating losses by avoiding the buildup of infection pressure. There are many advantages to keeping the infection pressure low in poultry houses:

- Low numbers of oocysts ingested result in minimal numbers of intestinal cells destroyed.
- Natural immunity can be established.
- The selection for drug resistance is minimized when dynamic programs (shuttle, rotational) are used to maintain low infection pressure.
- Good management practices including cleaning and disinfecting houses between flocks; good hygiene and biosecurity on the farm; good ventilation; balanced feed; and sufficient clean water.

Goal 2 - Preserving a sensitive coccidia population

Secondly, coccidia have proven to be extremely adaptable, leading to a significant concern on resistance issues. Therefore, in most cases, maintaining long-term coccidiosis control requires the use of multiple anticoccidial compounds. In recent years, shuttle and rotational programs have proven to be very effective in maintaining low infection pressure. The success of these programs is dependent on alternating anticoccidials from different categories. This way, a new anticoccidial is introduced and coccidiosis control is re-established before coccidia strains resistant to the first anticoccidial used develop.

Interpreting the clues of coccidial infection, species by species.

Site of Infection	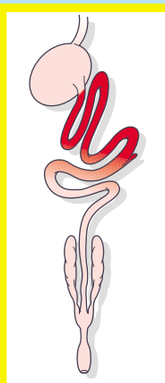	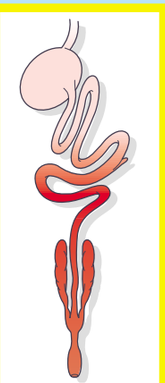	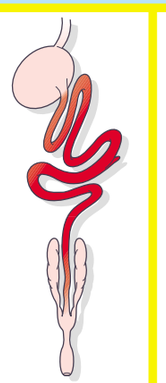	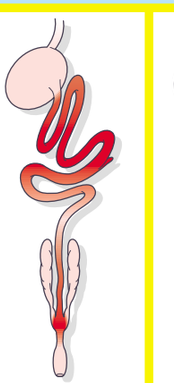	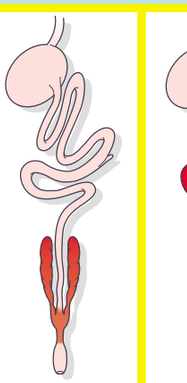	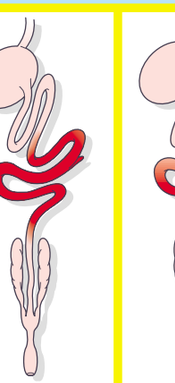	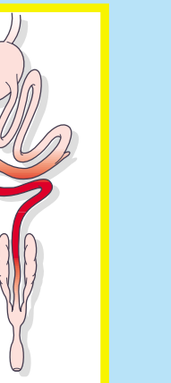
Species	*E. acervulina*	*E. brunetti*	*E. maxima*	*E. mivati*	*E. tenella*	*E. necatrix*	*E. mitis*
Oocyst Size	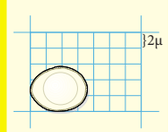 18.3 x 14.6	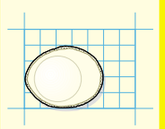 24.6 x 18.8	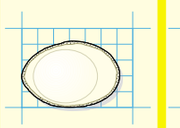 30.5 x 20.7	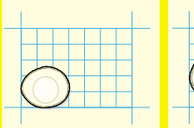 15.6 x 13.4	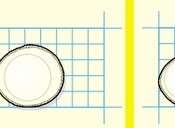 22.0 x 19.9	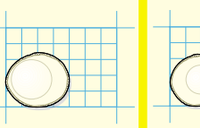 20.4 x 17.2	 15.6 x 14.2
Key Symptoms	Loss of appetite; drop in egg production; loss of weight; some diarrhea; chronic condition in layers.	Diarrhea; emaciation; some mortality in serious outbreaks.	Diarrhea; droppings may be flecked with blood; loss of appetite, emaciation; some deaths.	Unthriftiness; severe infections cause marked morbidity; drop in egg production.	Bloody droppings; marked drop in feed consumption; emaciation; high rate of mortality; lethargy is very noticeable.	Feed consumption drops; birds droopy; loss of weight; drop in egg production.	Diarrhea principal symptom; no mortality.
Postmortem Signs	Upper half of intestine affected; numerous grey-white streaks on gut wall visible.	Lower half of intestine affected; rectum, ceca and cloaca inflamed and thickened; entire mucosa may slough off in severe outbreak.	Dilation and thickening of lower half of intestine; gut filled with pink mucus or greyish brown exudate.	Early stages in anterior 1/3 of small intestine; later in lower small intestine, ceca and rectum; rounded lesions; congested and white opacities, blood-tinged to watery feces.	Ceca filled with blood; cheesy cecal core streaked with blood.	Upper third of small intestine; some degree of inflammation.	Entire small intestine may be affected; slight degree of inflammation.

Tools for strategic coccidial control.

Anticoccidial compounds are divided into three distinct categories of polyether ionophores, plus synthetic or chemical products. Each category of anticoccidial has its own characteristics that can make it the preferred choice under specific circumstances.

Polyether ionophores are compounds obtained through fermentation. Their mode of activity increases the permeability of cell membranes in targeted coccidia to a specific cation (positively charged ion). Increasing the flow of these ions disturbs the osmotic balance in the coccidia and destroys the parasite.

Instead of eliminating all the targeted oocysts, ionophores allow the cycling of a low number of parasites. This enhances the development of natural immunity. Ionophores can be divided by their chemical structure and precise mode of action into three categories, each offering its own unique advantages.

Monovalent ionophores are the most widely used anticoccidial compounds.

Monovalent glycoside ionophores are very effective against *E. tenella* and *E. maxima*.

Divalent ionophores are very effective against *E. tenella* and *E. maxima*.

Synthetic or chemical anticoccidials tend to be very effective at eliminating all or practically all oocysts from the flock. As a result, these products can be very valuable when infection pressure gets out of control and needs to be lowered quickly. Although these compounds are very effective in reducing the numbers of oocysts, the lack of cycling oocysts minimizes the development of natural immunity in the birds. Most coccidia develop resistant strains to this group of anticoccidials more quickly than to ionophores.

Methods for success.

There are three basic strategies for employing anticoccidials to keep infection pressure low:

Shuttle Programs — The use of two or more anticoccidials during the life cycle of the flock. A typical program would involve using an anticoccidial compound from one category for the starter period, followed by a drug from a different category for the remaining life of the broilers.

Rotation Programs — The use of anticoccidial compounds from different categories in successive flocks. The goal here is to use the most effective anticoccidial for the conditions present and to change compounds before resistant strains can develop and increase infection pressure. The rotation is typically based on the relative efficacy of each anticoccidial. Sensitivity to the different compounds may vary for reasons such as previous use patterns or seasonal considerations, because temperature and humidity can influence the types of coccidial challenges that are most likely to be confronted. Many producers consider changes to their program twice a year.

Straight/Full Programs — The consistent use of only one anticoccidial until the broilers are marketed. Efficiencies are gained from using a single product in the feedmill and easier logistics. It can be used for one or for many flocks of birds. This method presents the greatest risk from resistant strains of coccidia.

Natural treatments.

The application of prebiotics, probiotics, essential oils and phytogenics to improve the overall health of the gut of the bird helps reduce the impact of coccidiosis. A population of beneficial bacteria is always better than pathogenic bacteria, since coccidia weaken the gut wall and can facilitate the passage of pathogenic bacteria through the gut wall. The feeding of prebiotics, probiotics, essential oils and phytogenics will not stop the coccidia through "competitive exclusion" but, it does provide nutrients and/or beneficial bacteria that strengthen gut health to minimize the impact of coccidia.

EnteroBac is a specially formulated proprietary blend of probiotic, prebiotic and phytogenic compounds designed to support intestinal health thus improving immune response to optimize bird performance as well as preventing secondary complication such as necrotic enteritis and coccidiosis. QTI specifically formulated and combined a direct fed microbial to promote beneficial intestinal microflora with phytogenic compounds to support intestinal function.

Overall, tests demonstrate that Enterobac can be used alone, or concurrently, as a complement to the use of live cocci vaccines. Tests have shown this specifically formulated product helped deliver significant improvements in FCR as well as significant reduction in number of ooysts shed during critical periods of the growth cycle.

- Numerous Broiler Battery Studies– Consistently remediated enteritis
- Two Floor-pen studies– Improved Weight Gain & FCR (vs. Salinomycin, Coccivac-B & Non-treated control)
- Research shows reduced Oocyst shedding without sacrificing immunity
- Studies indicate remediation of enteric lesion scores
  - full program or vaccine augmentation programs
  - significantly reduced NE lesion scores compared to Stafac in intensive necrotic enteritis challenge models
- Studies indicate a reduced level of fecal shedding of Staphylococcus